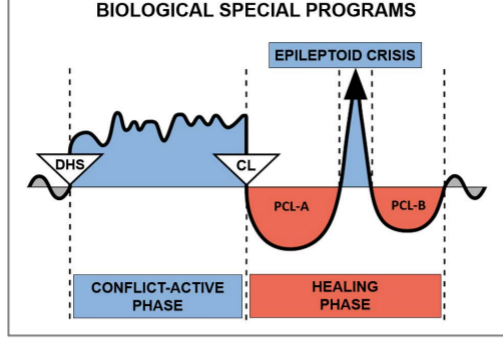


Case study by Dr. Alvin De Leon



CASE: 26

DATE: January 2012

CLIENT: 51 year old right-handed female

Subjective Complaint: The client presented in the office for a GNM perspective on a **skin lesion** she had **in the area of her right breast**. She reports that she noticed the raised, brownish, lesion with irregular borders 3-4 days ago. She indicates that she had just returned from a very stressful trip to Europe for her mother's funeral. She felt that the skin lesion showed up shortly after arriving home. She states that she was on her way to the walk-in clinic to get it checked out, but was very worried about what she would be told, particularly because she often frequented tanning salons. She also reports feeling very strong heart palpitations just before going to Europe and that they have been worse since returning home after the funeral.

Organs Affected: Corium skin

Embryonic germ layer: old mesoderm

Brain control center: cerebellum

Organs Affected: Myocardium

Embryonic germ layer: mesoderm

Brain control center: cerebral medulla

GNM Explanation: **Corium skin: attack conflict, feeling soiled or disfigured in the area of the skin affected.** The area of the skin feeling attacked produces a compact melanoma during the **Conflict-Active Phase** in order to strengthen the skin and to protect the area from further attacks of this kind. The melanoma will be decomposed in the **Healing Phase** with the help of mycobacteria. **Myocardium: conflict of feeling completely overwhelmed in relation to her partner** affecting the left myocardium with myocardial necrosis during the **Conflict-Active Phase** and heart palpitations during the **Epileptoid Crisis**. The client will need to identify her original conflicts in order to complete both Biological Special Programs (SBS).

GNM Understanding: The client recognized that her heart palpitations are related to her stress of having to go back to Europe for her mother's funeral. She admits that she had a falling out with her mom's brother who she has not spoken to in many years. She recalls feeling very anxious about having to go back for the funeral and possibly having a confrontation with her uncle at the funeral (**her DHS affecting the myocardium**). She indicates that to her surprise there were no problems with any family members and that everyone was very respectful. Therefore, she may have entered the healing phase regarding the myocardium SBS, causing heart palpitations, once she returned home from Europe.

The client recognized that the conflict linked to the skin lesion in the breast area is related to her heart palpitations. She relates that her heart palpitations began to be more frequent and stronger which made her feel very anxious, as her husband and father passed away from heart problems. She also reports having a good friend who was born with a heart problem which required her to have multiple heart surgeries throughout her life. She indicates that this friend recently passed away in the middle of another heart surgery which was a shock, as they had emailed each other the day prior. She recognized that her heart palpitations are related to her fears of having to have heart surgery which her body could interpret as an "attack against the skin" (**her DHS**). When I asked her to place her hand on where she experiences the heart palpitations, she placed her left hand directly over the skin lesion near the top of the right breast area. We worked on her understanding of the correlation between the "attack conflict" and her skin lesion and also to address the conflict related to her heart palpitations.

Results: One week later, the client reported that the skin lesion “miraculously” disappeared after two days. She indicates that she decided not to go to the walk-in clinic and instead worked on calming herself down in order to minimize her overall anxiety. She was very happy to also report that she has not had any heart palpitations since.

For clarification of specific terms, please consult the English “Five Biological Laws” document

Source: www.LearningGNM.com

© LearningGNM.com

DISCLAIMER: The information in this document does not replace professional medical advice.