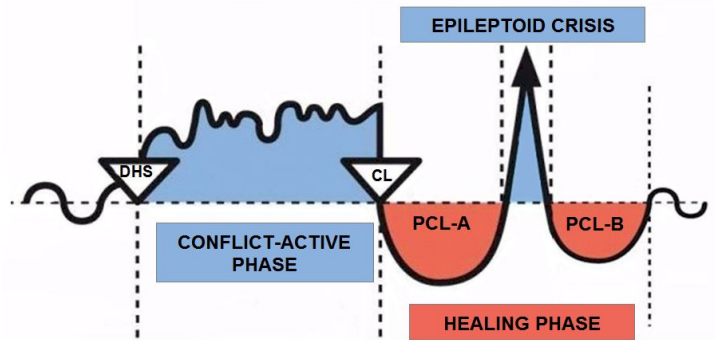


CONJUNCTIVITIS**DATE:** July 29, 2019**CLIENT:** 7 year-old right-handed male

Subjective Complaint: The mother of the young client stated that her son has recurring **conjunctivitis (pink eye) in his left eye**. She had taken her son to the doctor on three different occasions where antibiotics were prescribed. On the fourth doctor's visit, she was told to take her son to an eye specialist since he continues to have an issue with his eye.

Observation: There were no symptoms at that time.

Organs Affected: Conjunctiva

Embryonic germ layer: ectoderm

Brain control center: cerebral cortex (sensory cortex)

GNM Explanation: The biological conflict linked to the conjunctiva, cornea, and lens is a visual separation conflict of having lost sight of someone, for example, of a loved one who has moved away, left, or has died. During the **Conflict-Active Phase**, there is ulceration in the conjunctiva, cornea, or lens. During the **Healing Phase**, the cell loss is restored and replenished. Conjunctivitis (pink eye) is with red, burning, itchy, and watery eyes, which occurs when the conjunctiva is in healing. The inflammation often involves the inside of the eyelids. The client is currently in a **Hanging Healing**. The conflict and **tracks** have to be identified in order to complete the healing.

When asking the boy who he missed seeing, he immediately perked up and said, with a smile, "my mom"!

GNM Understanding: Both the mother and the client understood the GNM explanation. The client's mother stated that the conflict must be related to the times when he is away with his father for an extended period of time (longer than a weekend). During the time with his father, the client is not permitted to use his cell phone; therefore, not able to use FaceTime (video calling) to see his mom (**his DHS**). The client decided to take his moms picture so that he could see her whenever he wanted and was eventually allowed to Facetime her while away. The client was able to make the connection that his pink eye was related to not seeing his mom for an extended period of time which allowed him to complete the healing.

Results: The mother reported that her son's eye had just a slight irritation (itching) after the next extended visit with his father but his pink eye did not return after he was allowed to use his cell phone to Facetime her. The client's pink eye has not returned in over five months although he has been away from his mom for extended periods of time.

For clarification of specific terms, please consult the English "Five Biological Laws" document.

Source: www.LearningGNM.com