

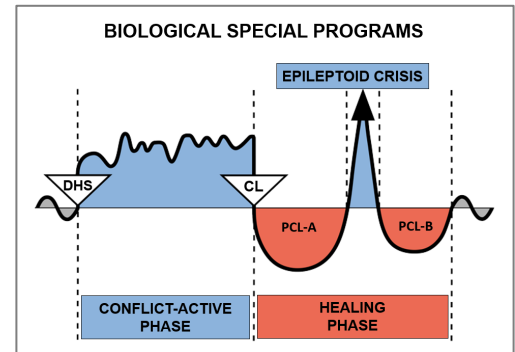
Case study by Dr. Alvin De Leon



CASE: 64

DATE: October 2017

CLIENT: 25 year old right-handed female



Subjective Complaint: The client was seen in the clinic for knee pain and other symptoms that were starting to resolve. She was curious about a GNM explanation for a **skin rash in between her third and fourth finger on both hands** that started to present only a few weeks ago. She admits that the rash becomes itchy at times. She also wondered why it was on a very specific area of her hands and not anywhere else on her body.

Observation: A mild skin rash with some redness and dry skin was observed in between the third and fourth finger of both hands and also on the inside of her right wrist. It was not necessarily warm to touch (see photos A and B, page 3).

Organs Affected: Epidermis (outer skin)

Embryonic germ layer: ectoderm

Brain control center: cerebral cortex (sensory cortex)

GNM Explanation: The epidermis is related to a separation conflict, experienced as “wanting to separate” or a “fear of separation”. This Biological Special Program involves ulceration of the affected skin during the **Conflict-Active Phase** and tissue restoration during the **Healing Phase** which presents as itchiness, hypersensitivity and a rash. She is currently in the Healing Phase or potentially in a **Hanging Healing**. Her original conflict (DHS) must be identified and brought to her awareness in order for her Biological Special Program to be completed.

GNM Understanding: The client understood the GNM explanation and indicated that her conflict might be related to the unexpected separation from her dog, who passed away suddenly a few months ago (**her DHS**)*. She admits that the last few months have been a difficult time for her, and that she has only recently started to overcome the loss. This could explain why her rash started to show up, as she began to deal with the unexpected separation.

When asked why she associates being separated from her dog with those specific areas of her hands, she realized that when she would pet her dog, his ears would fall in between her third and fourth fingers as she would rub the sides of his face with both hands.

The client was asked to make the connection that the rash on her hands is related to the unexpected separation from her dog. It was recommended that she continue to work on changing her perspective of the situation, particularly because she is now in a better place regarding the loss.

Results: The client texted me photos of her hands 5 days later (see photos C and D, page 4), excited about how quickly the rash was disappearing. She was very pleased at her body's response once she became aware of the conflict.

**Important note: I would like to point out that during our initial discussion of her rash, we thought it was related to an issue at work that maybe brought up fears of separation from her parents. This was determined due to the chronology of the symptoms and the unexpected work incident. We thought those specific fingers may be related to how her parents might have held her hands as a child when she would cross the street. But she was not certain about a memory related to this. Due to time restraints, we decided to connect her rash to this "fear of separation" conflict from her parents, though we were not fully satisfied about the relationship to the specific region of her hands. After one week, there was no change in her symptoms. She was asked by her family to see a dermatologist due to fears of a possible ring worm causing the rash. It was on this follow-up visit (one week after the original rash was discussed) that we determined the separation conflict was related to the death of her dog.*

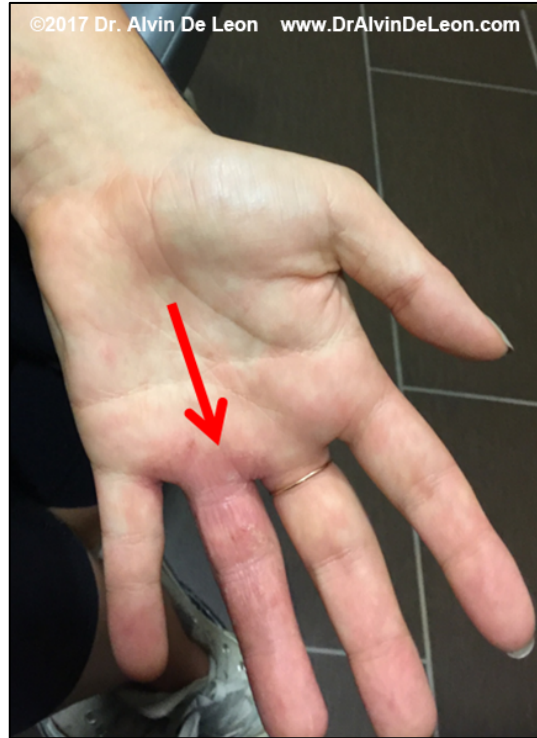
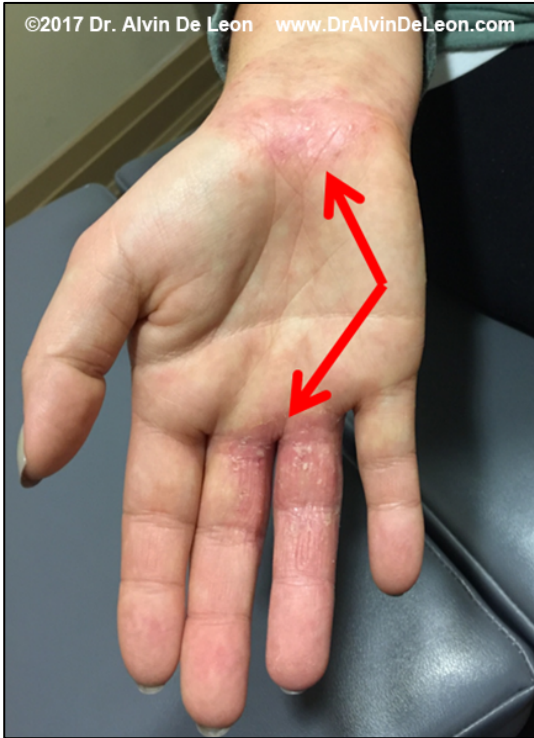
Photo A: Hand rash during first visit

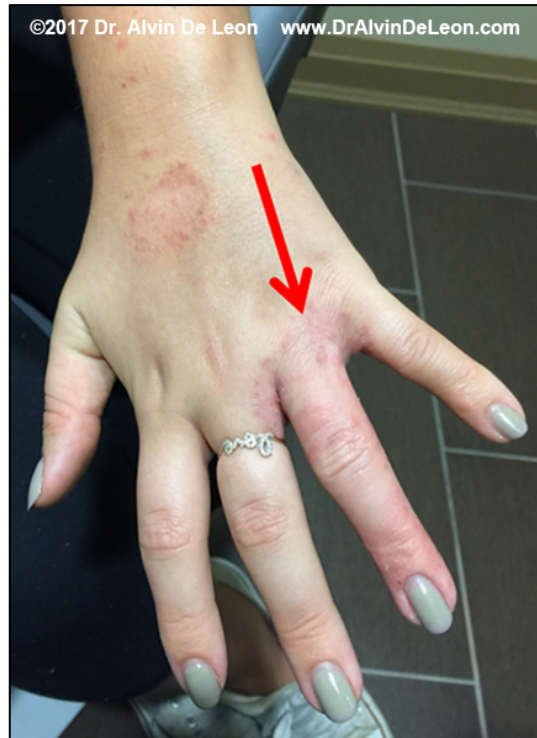
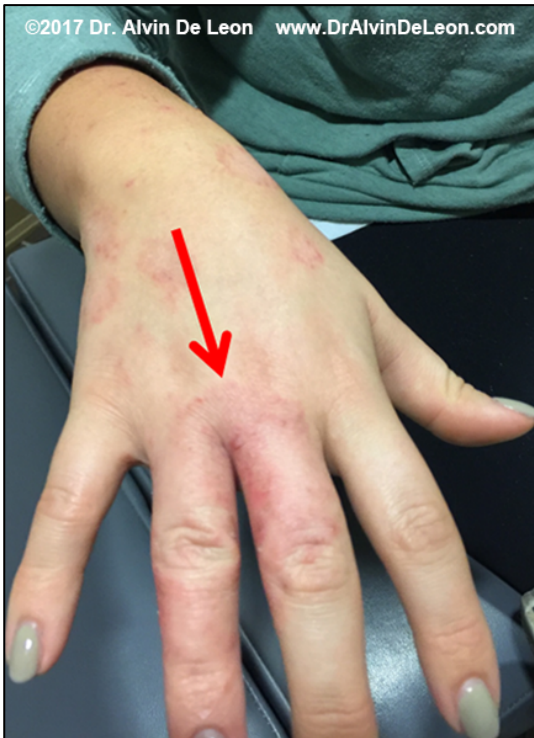
Photo B: Hand rash during first visit

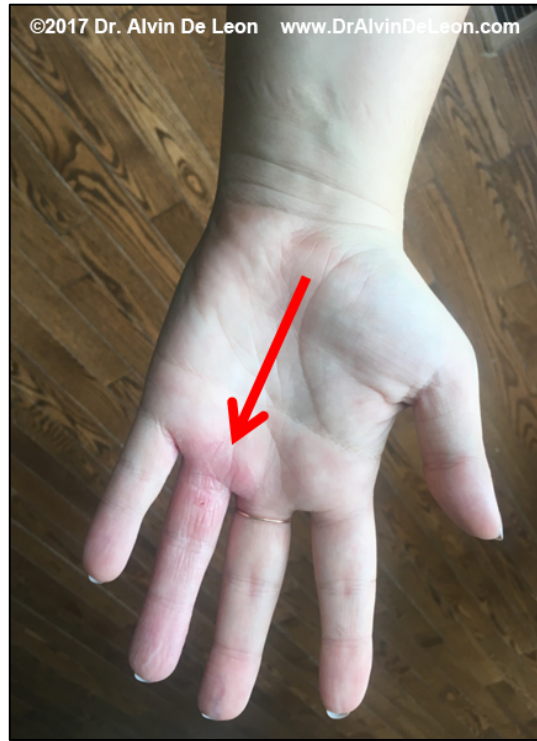
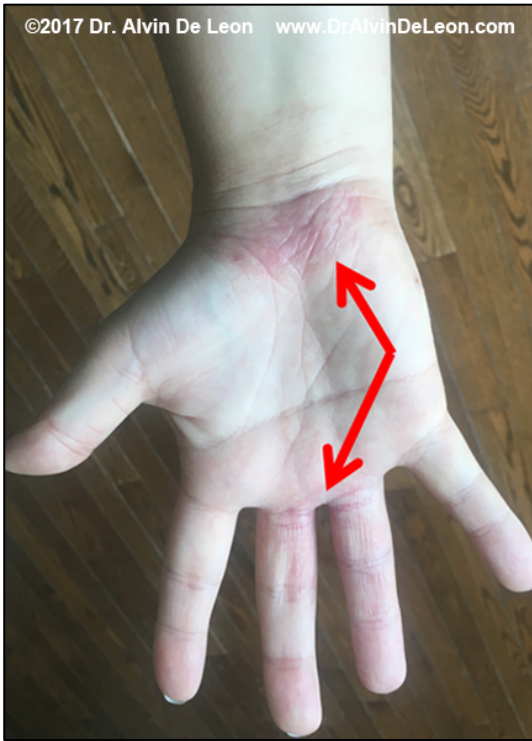
Photo D: Photos texted by patient 5 days later

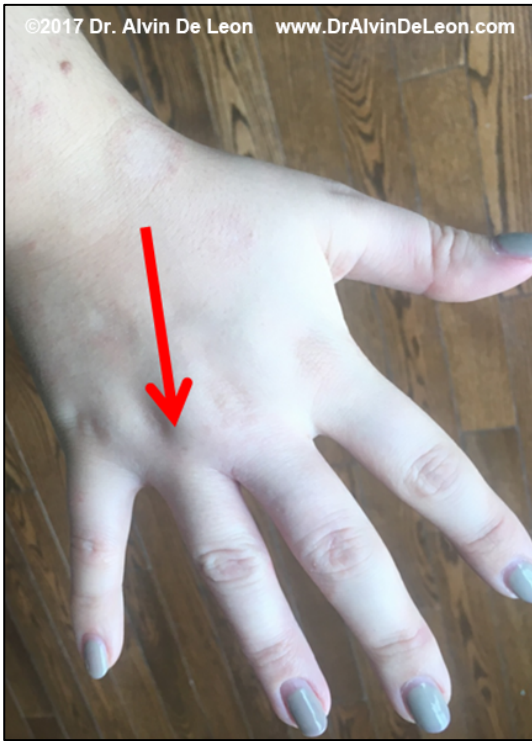

Photo C: Photos texted by patient 5 days later

For clarification of specific terms, please consult the English "Five Biological Laws" document

Source: www.LearningGNM.com