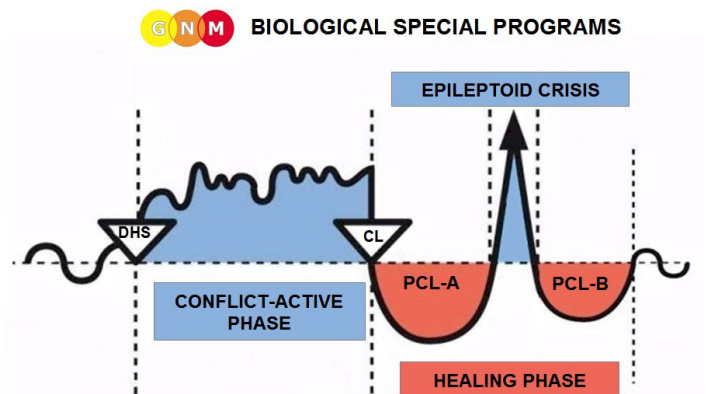




CASE #11

DATE: May 2011

CLIENT: 64 year-old right-handed female



Subjective Complaint: The client was recently diagnosed with **superficial phlebitis in her left calf veins** which were visibly swollen and enlarged. She did not complain of pain but was more concerned regarding the swelling.

Observation: Left calf superficial vein appears to be large and inflamed and slightly tender to palpation.

Organs Affected: **Left calf leg veins**

Embryonic germ layer: new mesoderm

Brain control center: cerebral medulla

GNM Explanation: **Left leg veins: ball and chain conflict; feeling tied down with respect to her mother/ child** causing necrosis of the leg vein during the **Conflict-Active Phase** and phlebitis during **Healing Phase**. The client will need to identify the original conflict in order to complete the Biological Special Program.

GNM Understanding: The client understood the explanation and recognized that her conflict is related to a doctor's visit for her husband who is currently dealing with dementia. She reports that the medical doctor told her that her husband's dementia is a "frontal lobe dementia" which is the worst form to have (**her DHS**). She indicates that this diagnosis made her feel "tied down" and nervous that she may not be able to handle more of what's involved with caring for her spouse, whom she now sees like a "child", hence the left leg vein (her mother/child side).

Results: Upon a follow-up visit 3 weeks later for another complaint, she mentioned that the swelling in her left calf resolved after 3 days. Her left calf now appeared normal in size with mild scar tissue palpated. She reports coming to terms with her new role in the relationship as she continues to deal with her spouse's health issues.

For clarification of specific terms, please consult the English "Five Biological Laws" document

Source: www.LearningGNM.com