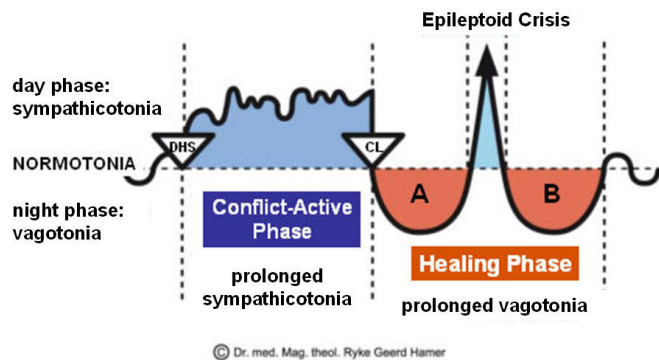




## CASE STUDY 63

**DATE:** March, 2013



**PATIENT:** 55 year old right-handed female

**Subjective Complaint:** The patient was coming in for low back pain symptoms that were starting to resolve. She was curious about a GNM explanation for a **skin rash on the inside (bend) of her left elbow**, which showed up only a few days ago on the weekend.

**Observation:** A mild skin rash with redness was observed on the bend of her left elbow. It was not necessarily warm to touch and the patient reported only mild itchiness.

**Organs Affected: Epidermis (outer skin):**

Embryonic Germ Layer: ectoderm

Brain Control Centre: cerebral cortex (sensory cortex)

**GNM Explanation:** The **epidermis** is related to a "**separation conflict**", experienced as "**wanting to separate**" or a "**fear of separation**". This Biological Special Program involves ulceration of the affected skin during the **Conflict Active Phase** and tissue restoration during the **Healing Phase** which presents as itchiness, hypersensitivity and a rash. The inside of the left elbow indicates "**not wanting to separate or a fear of separation**" from a mother/child (because she is biologically right-handed). She is currently in the healing phase or potentially in a hanging healing.

**GNM Understanding:** The client understood the GNM explanation and indicated that her conflict might be related to her daughter. She admits that earlier last week, she had a big argument with her daughter, who was going through a difficult time emotionally. She states that after their argument, her daughter left angrily and did not return home for a few days (**her DHS**). The client recognized that her rash showed up because her daughter finally came back home on the weekend. She indicates that things are not completely fine yet with her daughter, but that they are willing to work things out together.

The client was asked to make the connection that her left elbow rash is related to the unexpected separation from her daughter. It was recommended that she continue to work on changing her perspective of the situation, particularly because her daughter is now back home and willing to work through things together.

**Results:** The client returned for a follow-up visit one week later. We continued to treat her musculoskeletal symptoms; however she reported that the skin rash disappeared within a few days of our last visit. She indicates that she no longer has any rash on the inside of her left elbow and that her daughter has decided to move back home again.

The client reported during a visit 2 months later, that she continues to have no rash in her elbow. She also admitted that things have been better regarding her relationship with her daughter.

*For clarification of specific terms, please visit the glossary or site search feature in our GNM website*

**Extracted from: [www.LearningGNM.com](http://www.LearningGNM.com)**